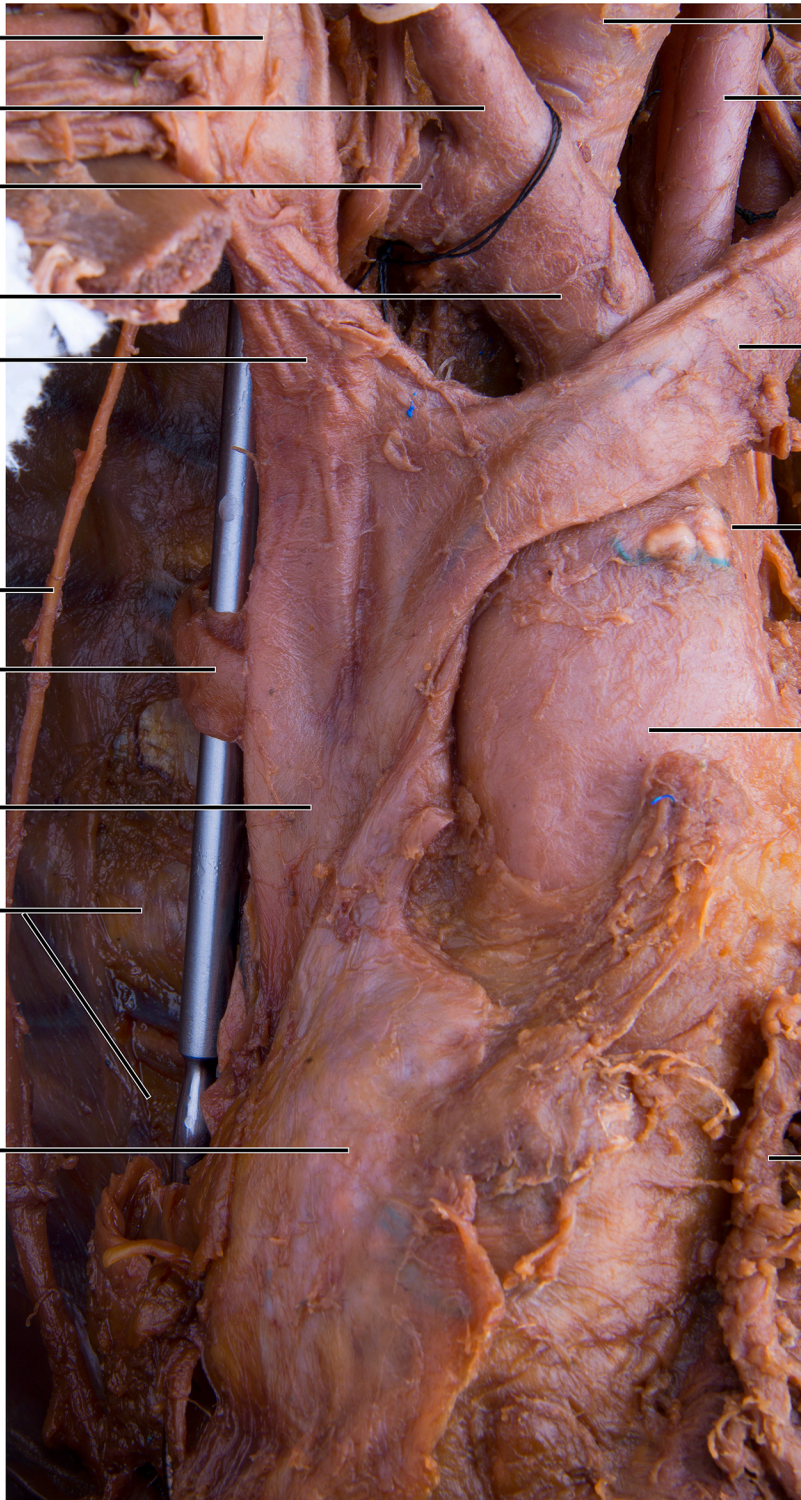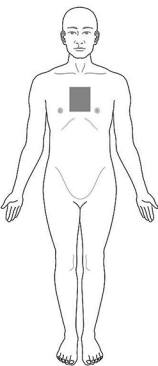


External Superior Features of the Heart 2  
Right Anterolateral View



Photography/Graphic Design: Richard Gatt®  
Research/Preparation: Paulina Ross