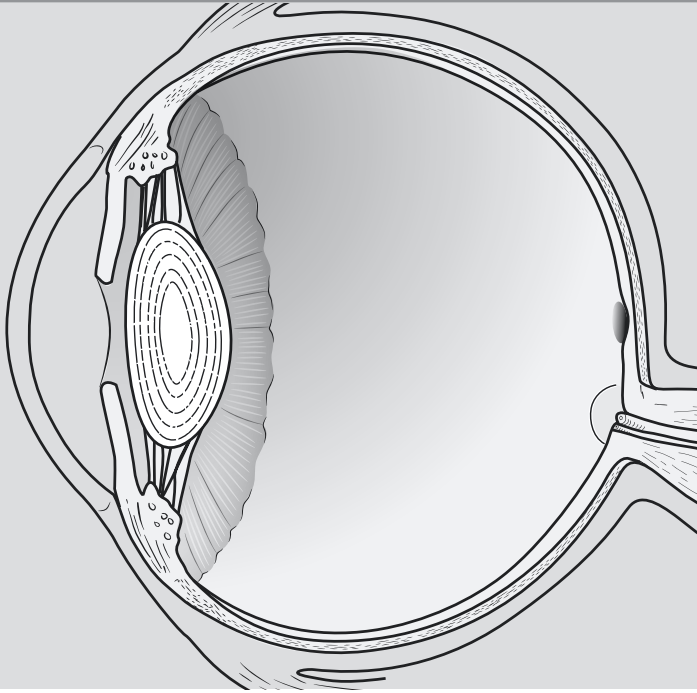


ACTIVITY



SPINAL CORD, SPINAL NERVES, SENSORY ORGANS

OBJECTIVES

- How to get ready:** Read CHAPTERS 16 AND 19, MCKINLEY ET AL., *HUMAN ANATOMY*, 2024 RELEASE. All text references are for this textbook. **You can also complete most of Table 3 BEFORE you come to lab.**
- Identify structures in the gross anatomy of the spinal cord on both models and donors or wet specimens.
- Identify structures in the cross section of the spinal cord on classroom models.
- Identify the nerve plexuses and specific nerves from each. **At this point, students are responsible for the specific muscles innervated by each peripheral nerve listed.**
- Identify structures from the human eye on models.
- Dissect a cow eye and identify the structures listed. **YOU MUST BRING GLOVES FOR THIS ACTIVITY.**
- Identify structures of the ear on classroom models.
- Histology: Observe and identify structures in a histology slide of the cochlea.
- Before next class:** Preview Heart and Blood terms lists from SLCC Anatomy Laboratory website or your printed laboratory manual and your textbook.

Activity 8

TABLE 8-1. Gross anatomy of the spinal cord, posterior view	
STRUCTURE	TEXT REFERENCES & NOTES
<input type="checkbox"/> cervical enlargement	FIG. 16.1
<input type="checkbox"/> thoracic region of the spinal cord	
<input type="checkbox"/> lumbar enlargement (<i>or</i> lumbosacral enlargement)	
<input type="checkbox"/> conus medullaris	
<input type="checkbox"/> cauda equina	
<input type="checkbox"/> filum terminale	
<input type="checkbox"/> posterior median sulcus	FIG. 16.2B, 16.3
<input type="checkbox"/> anterior median fissure	
<input type="checkbox"/> anterior rootlets	FIG. 16.2B, 16.3
<input type="checkbox"/> posterior rootlets	
<input type="checkbox"/> spinal nerves <ul style="list-style-type: none"> <input type="checkbox"/> cervical spinal nerves (C1–C8) <input type="checkbox"/> thoracic spinal nerves (T1–T12) <input type="checkbox"/> lumbar spinal nerves (L1–L5) <input type="checkbox"/> sacral spinal nerves (S1–S5) <input type="checkbox"/> coccygeal spinal nerve (Co1) 	FIG. 16.1, 16.7–16.11
<input type="checkbox"/> denticulate ligaments	FIG. 16.1B

Spinal Cord, Spinal Nerves, Sensory Organs

TABLE 8-2. Cross-section of the spinal cord	
STRUCTURE	TEXT REFERENCES & NOTES
<input type="checkbox"/> central canal	FIG. 16.2, 15.6
<input type="checkbox"/> posterior median sulcus	FIG. 16.2B
<input type="checkbox"/> anterior median fissure	
<input type="checkbox"/> posterior (<i>or dorsal</i>) root	FIG. 16.2B, 16.4
<input type="checkbox"/> posterior rootlets	
<input type="checkbox"/> posterior (<i>or dorsal</i>) root ganglion	
<input type="checkbox"/> anterior (<i>or ventral</i>) root	
<input type="checkbox"/> anterior rootlets	
<input type="checkbox"/> gray matter <ul style="list-style-type: none"> <input type="checkbox"/> posterior (dorsal) horns <input type="checkbox"/> gray commissure <input type="checkbox"/> lateral horns <input type="checkbox"/> anterior (ventral) horns 	FIG. 16.3A & B
<input type="checkbox"/> white matter <ul style="list-style-type: none"> <input type="checkbox"/> posterior white columns (funiculus) <input type="checkbox"/> anterior white columns (funiculus) <input type="checkbox"/> lateral white columns (funiculus) 	FIG. 16.3A
SPINAL MENINGES & SPACES (superficial to deep)	
<input type="checkbox"/> epidural space	FIG. 16.2A
<input type="checkbox"/> dura mater	
<input type="checkbox"/> subdural space	
<input type="checkbox"/> arachnoid mater	
<input type="checkbox"/> subarachnoid space	
<input type="checkbox"/> pia mater	

Activity 8

TABLE 8-3. Major nerve plexuses and selected nerves: You are now responsible for the listed nerves, the muscles they innervate (only) from your muscle lab list, and sensory functions when appropriate. Refer to CHAPTER 12, CHAPTER 16, and your muscle tables from Activities 5 & 6 to fill in any blanks in the following tables.

STRUCTURE	MOTOR FUNCTION	SENSORY FUNCTION
<input type="checkbox"/> CERVICAL PLEXUS	FIG. 16.7, TABLE 16.2	
<input type="checkbox"/> phrenic nerve (also contains fibers from brachial plexus)	diaphragm	NONE
<input type="checkbox"/> BRACHIAL PLEXUS	FIG. 16.8, TABLE 16.3	
<input type="checkbox"/> long thoracic nerve	serratus anterior	NONE
<input type="checkbox"/> medial pectoral nerve	• pectoralis major • pectoralis minor	NONE
<input type="checkbox"/> lateral pectoral nerve	pectoralis major	NONE
<input type="checkbox"/> axillary nerve	• deltoid • teres minor	cutaneous sensation of upper lateral shoulder
<input type="checkbox"/> median nerve	anterior forearm muscles (<i>list 6</i>)	tips of lateral three digits lateral palmar surface of hand
	1.	
	2.	
	3.	
	4.	
	5.	
<input type="checkbox"/> musculocutaneous nerve	• biceps brachii (both heads) • brachialis • coracobrachialis	lateral forearm
<input type="checkbox"/> ulnar nerve	• flexor carpi ulnaris • flexor digitorum profundus (medial ½) • most hand muscles	ring finger and pinky

Spinal Cord, Spinal Nerves, Sensory Organs

TABLE 8-3. Major nerve plexuses and selected nerves: You are now responsible for the listed nerves, the muscles they innervate (only) from your muscle lab list, and sensory functions when appropriate. Refer to CHAPTER 12, CHAPTER 16, and your muscle tables from Activities 5 & 6 to fill in any blanks in the following tables.

STRUCTURE	MOTOR FUNCTION	SENSORY FUNCTION
□ radial nerve	posterior arm muscles (<i>list 3</i>)	most of the dorsal surface of the hand
	1.	
	2.	
	3.	
	posterior forearm muscles (<i>list 8</i>)	
	1.	
	2.	
	3.	
	4.	
	5.	
6.		
7.		
8.		
□ INTERCOSTAL NERVES	FIG. 16.6	
intercostal nerves branch from thoracic spinal nerves; do not form a plexus	intercostal muscles	anterior and lateral chest wall
□ LUMBAR PLEXUS	FIG. 16.9, 16.10, TABLE 16.4	
□ femoral nerve	anterior thigh muscles (<i>list 8</i>)	anterior and medial surfaces of thigh and leg; arch of foot
	1.	
	2.	
	3.	
	4.	
	5.	
	6.	
	7.	
	8.	

Activity 8

TABLE 8-3. Major nerve plexuses and selected nerves: You are now responsible for the listed nerves, the muscles they innervate (only) from your muscle lab list, and sensory functions when appropriate. Refer to CHAPTER 12, CHAPTER 16, and your muscle tables from Activities 5 & 6 to fill in any blanks in the following tables.

STRUCTURE	MOTOR FUNCTION	SENSORY FUNCTION
□ obturator nerve	medial thigh muscles (<i>list 5</i>)	proximal medial thigh
	1.	
	2.	
	3.	
	4.	
	5.	
□ SACRAL PLEXUS	□ FIG. 16.10, TABLE 16.5	
□ superior gluteal nerve	<ul style="list-style-type: none"> • tensor fasciae latae • gluteus medius • gluteus minimus 	NONE
□ inferior gluteal nerve	gluteus maximus	NONE
□ sciatic nerve (branches to tibial nerve and common fibular nerve)		
□ tibial nerve	plantar surface of foot	plantar surface of the foot and heel
	posterior thigh muscles (<i>list 4</i>)	
	1.	
	2.	
	3.	
	4.	
	posterior leg muscles (<i>list 5</i>)	
	1.	
	2.	
	3.	
	4.	
5.		
□ common fibular nerve (branches to deep fibular nerve and superficial fibular nerve)	biceps femoris (short head)	

Spinal Cord, Spinal Nerves, Sensory Organs

TABLE 8-3. Major nerve plexuses and selected nerves: You are now responsible for the listed nerves, the muscles they innervate (only) from your muscle lab list, and sensory functions when appropriate. Refer to CHAPTER 12, CHAPTER 16, and your muscle tables from Activities 5 & 6 to fill in any blanks in the following tables.

STRUCTURE	MOTOR FUNCTION	SENSORY FUNCTION
□ deep fibular nerve	anterior leg muscles (<i>list 3</i>)	
	1.	space between first and second toes
	2.	
	3.	
□ superficial fibular nerve	lateral leg muscles (<i>list 2</i>)	
	1.	distal anterior leg dorsal surface of foot
	2.	
□ pudendal nerve	muscles of perineum, external anal sphincter, external urethral sphincter	external genitalia

SENSORY ORGANS: EYE AND EAR

TABLE 8-4. Extrinsic eye muscles and accessory structures of the eye		
STRUCTURE		TEXT REFERENCES
EXTRINSIC EYE MUSCLES		
Muscle	Innervation	
<input type="checkbox"/> inferior oblique muscle	CNIII (oculomotor nerve)	FIG. 11.4
<input type="checkbox"/> inferior rectus muscle		
<input type="checkbox"/> superior rectus muscle		
<input type="checkbox"/> medial rectus muscle		
<input type="checkbox"/> lateral rectus muscle	CNVI (abducens nerve)	
<input type="checkbox"/> superior oblique muscle	CNIV (trochlear nerve)	
ACCESSORY STRUCTURES		
<input type="checkbox"/> palpebra (eyelid), superior and inferior		FIG. 19.9
<input type="checkbox"/> orbital fat pad		
<input type="checkbox"/> lacrimal gland		FIG. 19.9, 19.10
<input type="checkbox"/> nasolacrimal duct		
<input type="checkbox"/> lacrimal caruncle		

Activity 8

TABLE 8-5. Eye	
STRUCTURE	TEXT REFERENCES & NOTES
<input type="checkbox"/> optic nerve (CN II)	FIG. 19.11, 19.17
<input type="checkbox"/> conjunctiva	FIG. 19.9
LAYERS OF THE EYE WALL (superficial to deep)	
<input type="checkbox"/> fibrous tunic (outermost layer)	FIG. 19.11
<input type="checkbox"/> sclera	
<input type="checkbox"/> cornea	
<input type="checkbox"/> vascular tunic (middle layer)	FIG. 19.11
<input type="checkbox"/> choroid	
<input type="checkbox"/> ciliary body with ciliary muscles	
<input type="checkbox"/> iris	
<input type="checkbox"/> pupil	
<input type="checkbox"/> neural tunic (innermost layer)	FIG. 19.11, 19.13
<input type="checkbox"/> retina	
<input type="checkbox"/> optic disc (“blind spot”)	
<input type="checkbox"/> macula lutea	
<input type="checkbox"/> fovea centralis	
<input type="checkbox"/> ora serrata	

Spinal Cord, Spinal Nerves, Sensory Organs

STRUCTURE	TEXTBOOK REFERENCE & NOTES
<input type="checkbox"/> anterior cavity	FIG. 19.16, 19.11
<input type="checkbox"/> anterior chamber	
<input type="checkbox"/> posterior chamber	
<input type="checkbox"/> aqueous humor	
<input type="checkbox"/> lens	FIG. 19.16, 19.11
<input type="checkbox"/> posterior cavity (vitreous chamber)	FIG. 19.11, 19.16
<input type="checkbox"/> vitreous humor	

Activity 8

COW EYE DISSECTION INSTRUCTIONS

- WEAR GLOVES FOR THIS ACTIVITY
- Wash hands before and after dissection

1. Obtain dissection pan, dissecting tools, and a fresh cow eye. Observe the following external anatomical structures before beginning your dissection.
 - **cornea**
 - **extrinsic eye muscles**
 - **optic nerve**
 - **orbital fat pad**
 - **sclera**
 - **iris**
 - **pupil**
2. Using scissors and forceps, remove the orbital fat pad and extrinsic eye muscles, leaving the **optic nerve** intact.
3. Using a scalpel, scissors, and forceps, cut the eye open by making a coronal incision through the tough, white **sclera**, which completely encircles the eye. You should end up with two halves of the eye, a back half that contains the optic nerve connected to the posterior surface of the eye, and a front half that contains the cornea on the anterior surface.

You may notice a clear, thin liquid leaking out of the eye. This is the **aqueous humor**.

If you notice a clear, jelly-like fluid leaking out of the vitreous chamber, this is the **vitreous humor**. The function of the vitreous humor is to hold the retina against the wall of the eye.

In the cow eye, a lot of the **choroid** contains black pigment, which may become mixed with the vitreous humor when the eye is cut open.

Look for the yellowish or pinkish thin, delicate membrane lining the inner surface of the eye and attached to the posterior of the eye at the optic nerve. This is the **retina**, which contains the neurons responsible for detecting light and sending vision information to the brain.

4. Find the **optic nerve** and locate the spot on the inside of the eye where the optic nerve attaches to the eye (the location where the retina attaches to the back of the eye on the inside). This spot within the eye is called the **optic disc** or **blind spot**. This spot has no neurons that can detect light (photoreceptors), and it is where the axons from the retina leave the eye and travel to the brain through the **optic nerve** (CNII).
5. Move the retina aside and observe the inner wall of the posterior half of the eye. Notice the colorful, iridescent **tapetum lucidum**. This structure is not present in human eyes, but is present in animals that are able to see well in dim light. It reflects light around within the eye, so that dim light can still activate numerous photoreceptors. It is the reflection of the light from the tapetum lucidum that causes a cat's eyes (as well as other animal species) to shine or glow when a light shines on them at night.

Spinal Cord, Spinal Nerves, Sensory Organs

6. Note the anterior portion of the eye. Notice the semi-transparent **lens**, which is suspended in place by a ring of black-colored tissue called the **ciliary body**. The cavity anterior to the lens is the **anterior chamber** of the eye. In a living organism, it is filled with a clear, thin fluid called **aqueous humor**.
7. Remove the lens from the eye. You can see through it. Place it on a piece of paper containing some text and note the change in appearance of the text. What did you see?
8. Identify the following structures on the interior of the dissected cow eye:
 - anterior chamber**
 - choroid**
 - ciliary body**
 - lens**
 - optic disc**
 - posterior chamber**
 - retina**
 - tapetum lucidum**
 - vitreous humor**

When you have finished the dissection, clean up the area. Dispose of the cow eye as directed. Clean, dry, and put away your instruments and dissection tray in order to receive credit for your participation grade for the day.

Activity 8

TABLE 8-7. Ear: The ear is composed of three regions: the external ear, located mostly on the outside of the head, and the middle and inner ear, which are housed within the petrous portion of the temporal bone.

STRUCTURE	TEXT REFERENCES & NOTES
EXTERNAL EAR	
<input type="checkbox"/> auricle (pinna)	FIG. 19.19, 19.20
<input type="checkbox"/> external acoustic meatus (<i>or</i> canal)	
<input type="checkbox"/> tympanic membrane (eardrum; the partition between external and middle ear)	
MIDDLE EAR	
<input type="checkbox"/> auditory ossicles (lateral to medial) <ul style="list-style-type: none"> <input type="checkbox"/> malleus <input type="checkbox"/> incus <input type="checkbox"/> stapes 	FIG. 19.19, 19.20
<input type="checkbox"/> oval window (opening to the scala vestibuli) <input type="checkbox"/> round window (exit of the scala tympani)	
INNER EAR	
<input type="checkbox"/> cochlea (hearing)	FIG. 19.26A & B, 19.21
<input type="checkbox"/> vestibule <ul style="list-style-type: none"> <input type="checkbox"/> utricle <input type="checkbox"/> saccule 	
<input type="checkbox"/> semicircular canals <ul style="list-style-type: none"> <input type="checkbox"/> semicircular ducts <input type="checkbox"/> ampulla (pl. ampullae) 	
<input type="checkbox"/> vestibulocochlear nerve (CNVIII)	FIG. 19.19, 19.24, 19.26
<input type="checkbox"/> vestibular branch	
<input type="checkbox"/> cochlear branch	
<input type="checkbox"/> auditory tube	FIG. 19.19, 19.27

TABLE 8-8. Structure of the cochlea and spiral organ (histology slide and model)

STRUCTURE	TEXT REFERENCES & SKETCH
<input type="checkbox"/> cochlear branch of CNVIII	FIG. 19.19, 19.21, 19.26 B & C
<input type="checkbox"/> scala vestibuli	
<input type="checkbox"/> scala media / cochlear duct	
<input type="checkbox"/> scala tympani	
<input type="checkbox"/> spiral organ (organ of corti) <ul style="list-style-type: none"> <input type="checkbox"/> basilar membrane <input type="checkbox"/> hair cells <input type="checkbox"/> tectorial membrane <input type="checkbox"/> vestibular membrane 	

Activity 8

STUDY AIDS FOR NERVOUS SYSTEM II

Helpful terms for Nervous System II

ANATOMICAL TERMS	DESCRIPTION
ampulla	local dilation of a tube
auricle	little ear
basilar	base
cervical	pertaining to the neck
choroid	like a membrane
cochlea	snail
conus	cone
cornea	horn
fovea	pit (smaller than a fossa)
humor	liquid
incus	anvil
iris	rainbow
lacrimal	tear (drop)
lutea	yellow
macula	spot
malleus	hammer
ora serrata	serrated edge
ossicle	small bone
phrenic	diaphragm
sacculle	small bag (smaller than utricle)
scala	stairs
sclera	hard
stapes	stirrup
tectorial	covering or roof
tympanic	tympanum = a drum
utricle	small bag (larger than sacculle)
vestibule	entrance hall