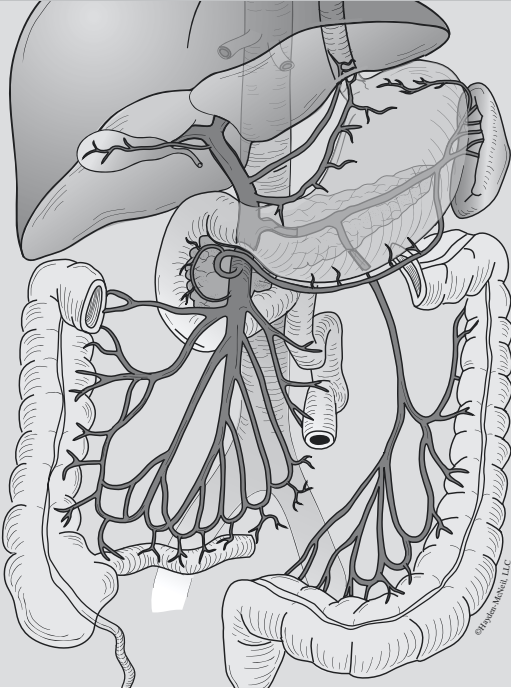


## ACTIVITY



# 110

## VESSELS AND CIRCULATION

---

### OBJECTIVES

- **How to get ready:** Read CHAPTER 23, MCKINLEY ET AL., *HUMAN ANATOMY*, 2024 RELEASE. All text references are for this textbook.
- Observe and sketch histology slide of an artery and a vein and identify structures on each. You can do this using your textbook or the laboratory PowerPoint **BEFORE LAB**.
- Identify structures and vessels involved in pulmonary circulation on donors and classroom models.
- Identify structures and vessels involved in systemic circulation (by region) on donors and classroom models. **YOU MUST BRING GLOVES FOR THIS ACTIVITY.**
- Complete and study the six assigned blood traces.
- **Before next class:** Preview Respiratory and Digestive terms lists from SLCC Anatomy Laboratory website or your printed laboratory manual and your textbook.

# Activity 10

## VESSEL HISTOLOGY

**TABLE 10-1. Microscopic comparison of an artery and a vein:** Obtain a prepared slide or a photo demonstrating cross sections of an artery and a vein. Distinguish between an artery and a vein and identify the following structures.

STRUCTURE	TEXT REFERENCES AND SKETCH
<input type="checkbox"/> <b>artery</b>	FIG. 23.1, 23.2, 23.3 TABLE 23.1
<input type="checkbox"/> lumen	
<input type="checkbox"/> tunica externa	
<input type="checkbox"/> tunica media	
<input type="checkbox"/> tunica intima	
<input type="checkbox"/> <b>vein</b>	
<input type="checkbox"/> lumen	
<input type="checkbox"/> tunica externa	
<input type="checkbox"/> tunica media	
<input type="checkbox"/> tunica intima	

## VESSELS: GROSS ANATOMY

**TABLE 10-2. Pulmonary circulation:** Pulmonary circulation carries deoxygenated blood from the right ventricle of the heart through the pulmonary trunk, and ultimately to the capillary beds of the lungs, then carries oxygenated blood back through the pulmonary veins to the left atrium.

STRUCTURE	TEXT REFERENCES AND NOTES
<input type="checkbox"/> right ventricle	FIG. 23.22
<input type="checkbox"/> pulmonary semilunar valve	
<input type="checkbox"/> pulmonary trunk	
<input type="checkbox"/> pulmonary arteries (left and right)	
<input type="checkbox"/> pulmonary capillaries	
<input type="checkbox"/> pulmonary veins (left and right)	
<input type="checkbox"/> left atrium	

## Vessels and Circulation

**Systemic Circulation:** Systemic circulation carries oxygenated blood from the left ventricle of the heart through the aorta, ultimately to the capillary beds of systemic body organs, then carries deoxygenated blood back to the right atrium. **Note: Coronary arterial and venous circulation are also part of systemic circulation, and were covered in the last laboratory activity.**

TABLE 10-3. General blood flow to and from the heart chambers	
STRUCTURE	TEXT REFERENCES AND SIGNIFICANCE
<b>ARTERIAL FLOW OUT OF THE HEART</b>	
<input type="checkbox"/> aorta	gives rise to all systemic arterial blood flow
<input type="checkbox"/> ascending aorta	gives rise to left and right coronary arteries and supplies the heart muscle
<input type="checkbox"/> aortic arch	gives rise to brachiocephalic trunk, left common carotid artery, and left subclavian artery
<input type="checkbox"/> descending aorta	gives rise to remainder of systemic arterial flow
<input type="checkbox"/> descending thoracic aorta	
<input type="checkbox"/> descending abdominal aorta	
<b>VENOUS RETURN TO THE HEART</b>	
<input type="checkbox"/> superior vena cava	returns blood from the head, neck, thorax, and upper limbs to the right atrium
<input type="checkbox"/> inferior vena cava	returns blood from the lower limbs, abdomen, and perineum to the right atrium
<input type="checkbox"/> coronary sinus	returns blood from the heart muscle to the right atrium

# Activity 10

TABLE 10-4. Blood flow through the head and neck	
STRUCTURE	TEXT REFERENCES AND SIGNIFICANCE
<b>ARTERIAL SUPPLY TO THE HEAD</b>	<b>FIG. 23.9, 23.10A &amp; C, 23.11A</b>
<input type="checkbox"/> brachiocephalic artery (trunk)	supplies right side of head and right arm
<input type="checkbox"/> right common carotid artery	supplies right side of head and neck
<input type="checkbox"/> right external carotid artery	supplies structures external to skull, right side
<input type="checkbox"/> right internal carotid artery	supplies internal skull structures and brain, right side
<input type="checkbox"/> left common carotid artery	supplies left side of head and neck
<input type="checkbox"/> left external carotid artery	supplies structures external to skull, left side
<input type="checkbox"/> left internal carotid artery	supplies internal skull structures and brain, left side
<input type="checkbox"/> vertebral arteries (left and right)	branches from subclavian arteries to supply more blood to brain
<input type="checkbox"/> basilar artery	formed from merging left and right vertebral arteries; supplies brain
<input type="checkbox"/> cerebral arterial circle ( <i>or</i> circle of Willis)	anastomosis of arteries supplying the brain in the sella turcica region
<b>VENOUS DRAINAGE OF THE HEAD</b>	<b>FIG. 23.10B &amp; C, 23.11B</b>
<input type="checkbox"/> dural venous sinuses	large veins in the dura mater that drain the cranium
<input type="checkbox"/> superior sagittal sinus	runs at the superior border of the falx cerebri, drains into the confluence of sinuses
<input type="checkbox"/> inferior sagittal sinus	runs at the inferior border of the falx cerebri, drains into the straight sinus
<input type="checkbox"/> straight sinus	drains into the confluence of sinuses
<input type="checkbox"/> confluence of sinuses	drains blood from the transverse and straight sinuses
<input type="checkbox"/> transverse sinuses	drain into the sigmoid sinuses
<input type="checkbox"/> sigmoid sinus	drains into the internal jugular veins
<input type="checkbox"/> internal jugular veins (left and right)	drain internal skull structures including brain
<input type="checkbox"/> external jugular veins (left and right)	drain external skull structures
<input type="checkbox"/> brachiocephalic veins (left and right)	formed by merging internal jugular veins and subclavian veins
<input type="checkbox"/> superior vena cava	formed by merging brachiocephalic veins
<input type="checkbox"/> vertebral veins (left and right)	drain internal skull structures into the brachiocephalic veins

# Activity 10

TABLE 10-5. Blood flow through the ventral body cavity	
STRUCTURE	TEXT REFERENCES AND SIGNIFICANCE
<b>ARTERIAL SUPPLY TO ABDOMINAL ORGANS</b>	<b>FIG. 23.12, 23.15, 23.17</b>
<input type="checkbox"/> celiac trunk (artery)	supplies stomach, part of duodenum, liver, pancreas, spleen
<input type="checkbox"/> splenic artery (to <b>spleen</b> , part of the immune and cardiovascular systems)	
<input type="checkbox"/> left gastric artery	
<input type="checkbox"/> common hepatic artery	
<input type="checkbox"/> hepatic artery proper	
<input type="checkbox"/> hepatic arteries (right & left)	
<input type="checkbox"/> right gastric artery	
<input type="checkbox"/> gastroduodenal artery	
<input type="checkbox"/> superior mesenteric artery	supplies most of small intestine and proximal large intestine
<input type="checkbox"/> renal arteries (left and right)	supply kidneys
<input type="checkbox"/> gonadal arteries (left and right)	supply ovaries or testes
<input type="checkbox"/> inferior mesenteric artery	supplies most of the large intestine
<b>VENOUS DRAINAGE OF THE ABDOMEN &amp; CHEST</b>	<b>FIG. 23.13, 23.14, 23.17</b>
<input type="checkbox"/> azygos vein	drains chest wall, ultimately into superior vena cava (SVC)
<input type="checkbox"/> hemiazygos vein	
<input type="checkbox"/> accessory hemiazygos vein	
<input type="checkbox"/> hepatic veins	drains liver into IVC after hepatic portal circulation
<input type="checkbox"/> renal veins (left and right)	drain kidneys into inferior vena cava (IVC)
<input type="checkbox"/> gonadal veins (left and right)	drains ovaries or testes into IVC or (left side) left renal vein

## Vessels and Circulation

**TABLE 10-5. Blood flow through the ventral body cavity**

STRUCTURE	TEXT REFERENCES AND SIGNIFICANCE
<b>HEPATIC PORTAL CIRCULATION</b>	
Venous drainage of most abdominal organs is a portal system—two capillary beds in a series connected by a portal vein. Blood drained from the abdominal organs is processed in the liver’s wide sinusoid capillaries before going back into systemic venous circulation. <b>FIG. 23.16, 23.17</b>	
<input type="checkbox"/> superior mesenteric vein	drains small intestine and part of large intestine into hepatic portal vein
<input type="checkbox"/> inferior mesenteric vein	drains most of large intestine into splenic vein, and then into hepatic portal vein
<input type="checkbox"/> splenic vein	drains spleen into the hepatic portal vein
<input type="checkbox"/> hepatic portal vein	delivers venous blood from the above vessels to the sinusoid capillaries of the liver, before blood is processed and returned to hepatic veins and then the IVC
<input type="checkbox"/> hepatic veins (left and right)	drains venous blood from liver into IVC

## Vessels and Circulation

<b>TABLE 10-6. Blood flow through the upper limb</b>	
STRUCTURE	TEXT REFERENCES AND SIGNIFICANCE
<b>ARTERIAL SUPPLY TO UPPER LIMB</b> (all vessels are paired)	<b>FIG. 23.19</b>
<input type="checkbox"/> subclavian artery	recall, left and right subclavian arteries have different origins, and also give rise to vertebral arteries
<input type="checkbox"/> axillary artery	supplies shoulder region
<input type="checkbox"/> brachial artery	supplies arm
<input type="checkbox"/> ulnar artery	supplies medial side of forearm and wrist
<input type="checkbox"/> radial artery	supplies lateral side of forearm and wrist
<input type="checkbox"/> superficial palmar arch	supplies superficial palm (formed by ulnar artery)
<input type="checkbox"/> deep palmar arch	supplies deep palm (formed by radial artery)
<input type="checkbox"/> digital arteries	supplies fingers (emerge from superficial and palmar arches)
<b>VENOUS DRAINAGE OF UPPER LIMB</b>	<b>FIG. 23.19</b>
<b>Superficial drainage</b> (all vessels are paired, left and right)	
<input type="checkbox"/> basilic vein	drains superficial, medial side of upper limb, usually into axillary vein
<input type="checkbox"/> cephalic vein	drains superficial, lateral side of upper limb, usually into axillary vein
<input type="checkbox"/> median cubital vein <i>OR</i> <input type="checkbox"/> median cephalic and median basilic veins	connects basilic and cephalic veins
<b>Deep drainage</b> (all vessels are paired, left and right, and some have two per side, as indicated)	
<input type="checkbox"/> digital veins	drain fingers into superficial and deep palmar arches
<input type="checkbox"/> superficial palmar venous arch	drain superficial palm into radial and ulnar veins
<input type="checkbox"/> deep palmar venous arch	drain deep palm into radial and ulnar veins
<input type="checkbox"/> radial veins (2)	drain deep, lateral side into brachial veins
<input type="checkbox"/> ulnar veins (2)	drain deep, medial side into brachial veins
<input type="checkbox"/> brachial veins (2)	drains arm; merges with basilic vein to form axillary vein
<input type="checkbox"/> axillary vein	drains axillary region; becomes subclavian vein
<input type="checkbox"/> subclavian vein	merges with internal jugular vein to form brachiocephalic vein
<input type="checkbox"/> brachiocephalic vein	merges with brachiocephalic vein from opposite side to form superior vena cava

# Activity 10

TABLE 10-7. Blood flow through the lower limb, pelvis, and perineum	
STRUCTURE	TEXT REFERENCES AND SIGNIFICANCE
<b>ARTERIAL SUPPLY TO THE LOWER LIMB, PELVIS, AND PERINEUM</b> (all vessels are paired)	<b>FIG. 23.20</b>
<input type="checkbox"/> common iliac artery	arises from the distal end of the descending abdominal aorta
<input type="checkbox"/> external iliac artery	supplies thigh and hip and becomes femoral artery after passing through inguinal ligament
<input type="checkbox"/> femoral artery	supplies thigh and becomes popliteal artery
<input type="checkbox"/> popliteal artery	supplies dorsal surface of knee and divides to form anterior and posterior tibial arteries
<input type="checkbox"/> anterior tibial artery	supplies anterior compartment of leg
<input type="checkbox"/> posterior tibial artery	supplies posterior compartment of leg and gives rise to fibular artery
<input type="checkbox"/> fibular artery	supplies lateral compartment of leg
<input type="checkbox"/> internal iliac artery	<b>FIG. 23.18, 23.20</b> supplies pelvis and perineum
<b>VENOUS DRAINAGE OF LOWER LIMB</b> (all vessels are paired)	<b>FIG. 23.20</b>
<b>Superficial drainage</b> (all vessels are paired)	
<input type="checkbox"/> great saphenous vein	drains superficial, medial side of lower limb into femoral vein
<input type="checkbox"/> small saphenous vein	drains lateral aspect of foot and posterior aspect of leg into popliteal vein
<b>Deep drainage</b> (all vessels are paired, left and right, and some have two per side, as indicated)	
<input type="checkbox"/> anterior tibial veins (2)	drains anterior compartment of leg
<input type="checkbox"/> posterior tibial vein (2)	drains posterior compartment of leg
<input type="checkbox"/> fibular veins (2)	drains lateral compartment of leg into posterior tibial veins



## Vessels and Circulation

**TABLE 10-7. Blood flow through the lower limb, pelvis, and perineum**

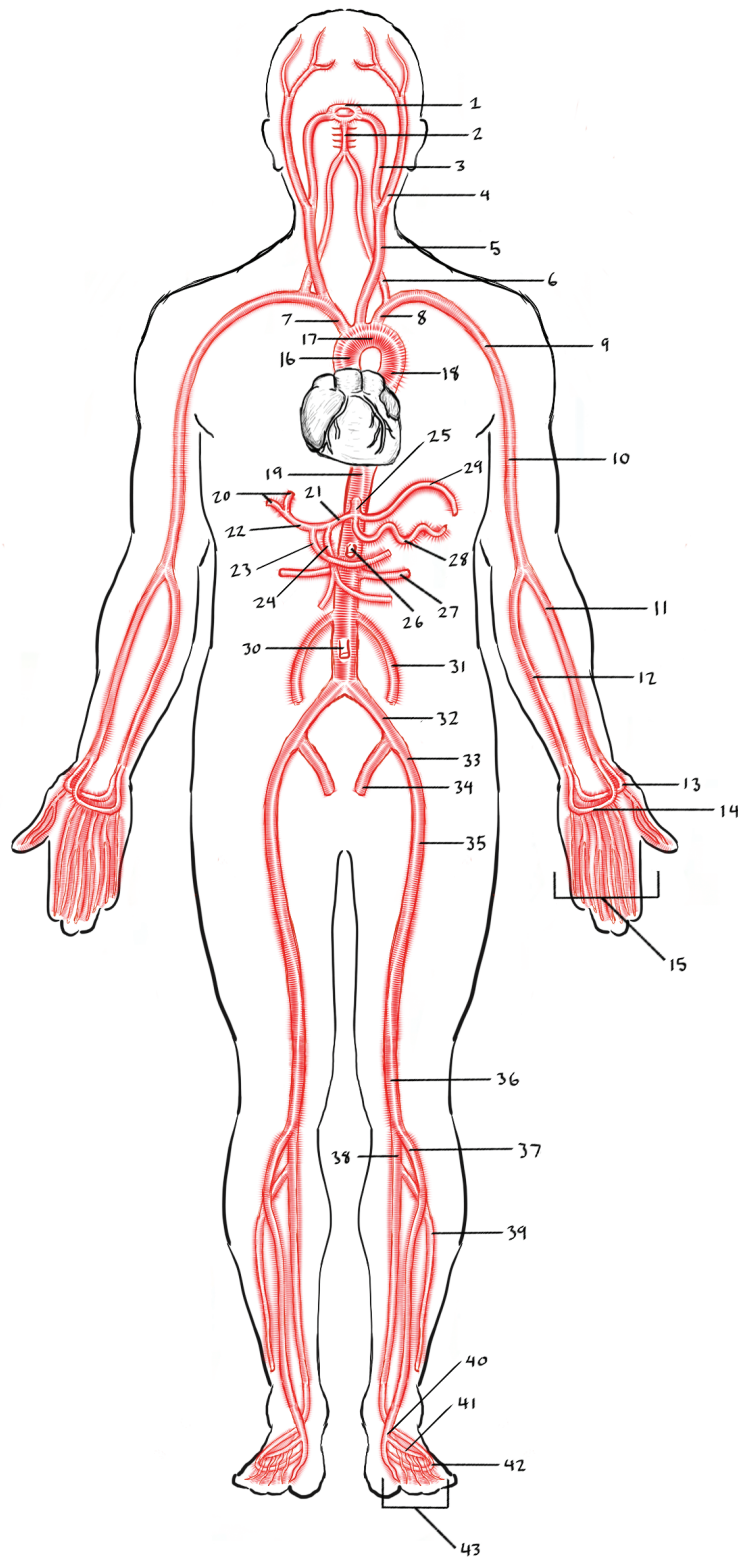
STRUCTURE	TEXT REFERENCES AND SIGNIFICANCE
□ popliteal vein	drains knee; formed from the merger of anterior and posterior tibial veins
□ femoral vein	drains thigh into external iliac vein
□ external iliac vein	drains thigh and hip
□ internal iliac vein	drains pelvis and perineum
□ common iliac vein	formed from uniting internal and external iliac veins; merges with common iliac vein from opposite side to become inferior vena cava

# Activity 10

## ARTERIAL CIRCULATION KEY

1	cerebral arterial circle	26	superior mesenteric artery
2	basilar artery	27	renal artery
3	internal carotid artery	28	splenic artery
4	external carotid artery	29	left gastric artery
5	common carotid artery	30	inferior mesenteric artery
6	vertebral artery	31	gonadal artery
7	brachiocephalic trunk	32	common iliac artery
8	subclavian artery	33	external iliac artery
9	axillary artery	34	internal iliac artery
10	brachial artery	35	femoral artery
11	radial artery	36	popliteal artery
12	ulnar artery	37	anterior tibial artery
13	deep palmar arch	38	posterior tibial artery
14	superficial palmar arch	39	fibular artery
15	digital arteries of hand	40	dorsalis pedis artery
16	ascending aorta	41	arcuate artery
17	aortic arch	42	plantar artery
18	descending thoracic aorta	43	digital arteries of foot
19	descending abdominal aorta		
20	hepatic arteries		
21	common hepatic artery		
22	hepatic artery proper		
23	right gastric artery		
24	gastroduodenal artery		
25	celiac trunk		

# Vessels and Circulation



©Illustration by Jose Oseguera.

FIGURE 10-9. Human arteries, anterior view.

# Activity 10

## VENOUS CIRCULATION KEY

1	superior sagittal sinus	26	superior mesenteric vein
2	transverse sinus	27	gonadal vein
3	sigmoid sinus	28	splenic vein
4	internal jugular vein	29	renal vein
5	vertebral vein	30	inferior mesenteric vein
6	external jugular vein	31	common iliac vein
7	brachiocephalic vein	32	external iliac vein
8	subclavian vein	33	internal iliac vein
9	cephalic vein	34	femoral vein
10	axillary vein	35	great saphenous vein
11	brachial vein	36	popliteal vein
12	basilic vein	37	small saphenous vein
13	median cubital vein	38	posterior tibial vein
14	radial vein	39	anterior tibial vein
15	ulnar vein	40	fibular vein
16	deep palmar arch	41	plantar venous arch
17	superficial palmar arch	42	dorsal venous arch
18	digital veins of hand	43	digital veins of foot
19	superior vena cava		
20	azygos vein*		
21	accessory hemiazygos vein*		
22	hemiazygos vein*		
23	inferior vena cava		
24	hepatic veins		
25	hepatic portal vein		
	*partially obstructed by the heart		

# Vessels and Circulation

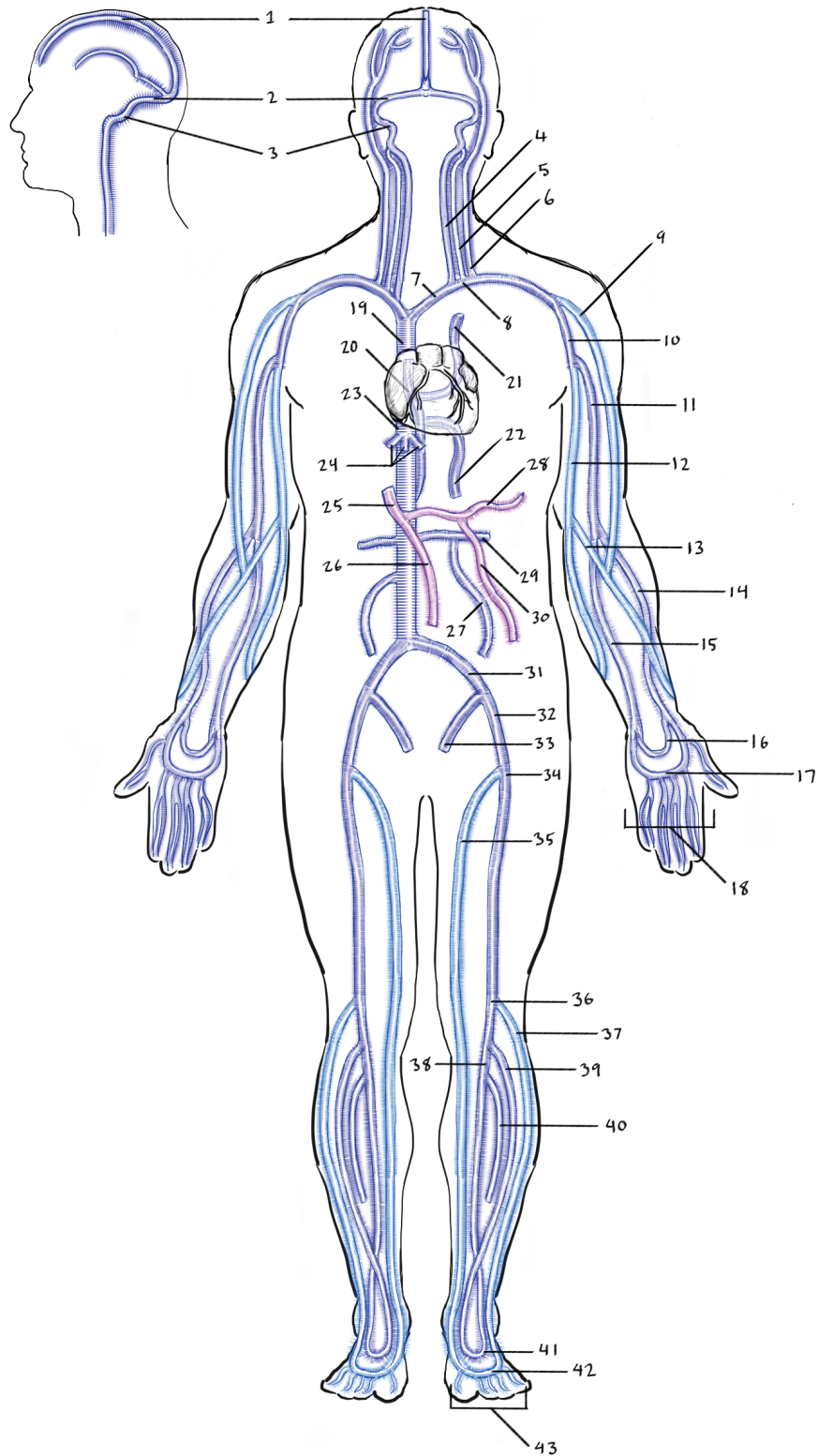


FIGURE 10-10. Human veins, anterior view.

# Activity 10

## BLOOD TRACE WORKSHEETS

### Student instructions:

A valuable exercise enabling you to understand how blood flows through the cardiovascular system is to trace a few of the routes a red blood cell would take in its journey through the body. In this exercise you will identify the missing structures in each of the six traces provided for you.

It is crucial that you avoid the temptation to get the answers from other students for two reasons: First, other students might make mistakes, which you likely wouldn't recognize if you simply copied from them. Second, the best way to learn these routes is to work through them yourself. Use the arterial and venous system flowchart handouts from the manual and the figures in your textbook (in CHAPTERS 22 AND 23) as guides to help you fill in the blanks. If you get stuck, or don't know where to begin, ask an instructor for assistance. The first trace is more completely filled in to give you an idea of how to proceed. FIGURE 23.9 is very helpful to give you a general idea of how to complete a blood trace.

### A few more directions:

- You only need to name the arteries and veins listed on your terms lists from your laboratory manual.
- Each trace should **begin and end with the left atrium of the heart**.
- Name all of the **valves** of the heart as they are encountered along the trace.
- Include a **capillary bed** in the target tissue, and another in the lungs, in the trace.
- On the traces to the wrist and ankle, name the *superficial* veins used on the return route to the heart.

Do not be intimidated... these aren't difficult once you get the idea!

**One of these traces will be on the final laboratory practical exam. The trace will be provided with blanks for you to fill in.**

### TRACE 1

From heart to medial side left wrist and back to heart. Use *superficial* veins in return to heart, then to lungs and back to heart:

**left atrium**

---

---

**ascending aorta**

**aortic arch**

---

**left axillary artery**

---

**left ulnar artery**

**capillary bed on medial side of left wrist**

---

**left axillary vein**

---

---

---

**right atrium**

---

---

**pulmonary semilunar valve**

---

---

**pulmonary capillary bed**

---

**left atrium**

# Activity 10

## TRACE 2

From heart to *liver*, delivering oxygenated blood to liver, back to heart, then to lungs and back to heart:

**left atrium**

---

---

---

---

---

---

---

---

---

---

---

---

**capillary bed in liver (hepatic sinusoid)**

---

---

**right atrium**

---

---

---

---

---

---

---

---

**left atrium**



**TRACE 3**

From heart to anterior side of right ankle and back to heart. Use the *superficial* route in leg on return to heart, then to lungs and back to heart:

**left atrium**

---

---

---

---

---

---

---

---

---

---

**right femoral artery**

---

---

---

---

---

---

---

---

---

---

**right atrium**

---

---

---

---

---

---

---

---

---

---

**left atrium**

Activity **10**

**TRACE 4**

From the heart to the distal part of the large intestine (sigmoid colon), and back to the heart, then to the lungs and back to the heart:

**left atrium**

---

---

---

---

---

---

---

---

---

---

---

---

---

---

---

---

---

---

---

---

---

---

---

**right atrium**

---

---

---

---

---

---

---

---

---

---

---

---

---

---

---

---

---

---

---

---

---

---

---

**left atrium**

**TRACE 5**

From heart to right side of frontal lobe of brain, then to lungs, and back to heart:

**left atrium**

---

---

---

---

---

---

---

---

---

---

---

---

---

---

---

---

---

---

---

---

---

---

---

**superior sagittal sinus**

---

---

---

---

---

---

---

---

---

---

---

---

---

---

---

---

---

---

---

---

---

---

---

**right atrium**

---

---

---

---

---

---

---

---

---

---

---

---

---

---

---

---

---

---

---

---

---

---

---

**left atrium**

# Activity 10

## TRACE 6

From heart to left testicle, then to lungs, and back to heart:

**left atrium**

---

---

---

---

---

---

---

---

---

---

**capillary bed in testicle**

---

---

---

**right atrium**

---

---

---

---

---

---

---

**left atrium**

### STUDY AIDS FOR VESSELS

Helpful terminology for Vessels

ANATOMICAL TERMS	DESCRIPTION
<b>azygos</b>	unpaired
<b>basilar</b>	base
<b>basilic</b>	inner
<b>brachiocephalic</b>	blood vessel related to upper limb and head
<b>cava</b>	hollow
<b>cephalic</b>	headward, outer
<b>lumen</b>	opening, space within a tube
<b>porta/portal</b>	a gate, to carry
<b>saphenous</b>	obviously visible (when varicose)
<b>tunica</b>	covering, shirt