

Orientation:

1. In this laboratory, you will have the rare privilege of using, in addition to models and non-human specimens, **prosected human cadavers** as a study tool for understanding human anatomy. Salt Lake Community College maintains strict compliance with federal legislation, the guidelines of the National Institutes of Health, and the University of Utah's Body Donor Program, from which the cadavers were acquired.
 - ❖ **These cadavers have been generously donated, meticulously prepared, and must be treated with the utmost respect and care.** Intentional misuse or disrespect of cadavers is grounds for dismissal from the course.
 - ❖ Guidelines for cadaver use:
 - **Photography, recording, or reproduction of cadaver-related material without the express permission of the Body Donor Program is expressly forbidden.**
 - Cadavers are delicate, and students have inadvertently damaged them by rough treatment. If you are uncertain, please ask a lab instructor or aide for guidance in using the cadavers. If you damage a cadaver accidentally, please alert your lab instructor, so that repairs may be attempted.
 - If you see another student disrespecting or damaging a cadaver, please alert your lab instructor immediately.
 - Students may NOT perform dissections or modifications on cadavers.
2. Other laboratory policies:
 - ❖ **Food and drink are never allowed in the laboratory.**
 - ❖ **Do not use pens and pencils on skeletal material or models** as it damages these hard to replace resources. Use a blunt probe or other provided instrument to point to these objects.
 - ❖ **Students must provide and wear gloves** when handling cadavers or non-human specimens.
 - ❖ **Attendance in your registered lab is required. The lab is 20% of the course grade.** Students who perform best in the course are those who come prepared for lab, work hard, and do not waste time in the laboratory.
 - ❖ **Visitors and guests are not allowed** in laboratories, including open labs.
 - ❖ **Materials, books, and models may not be removed or borrowed** from the laboratory or from the libraries or STEM center, for any reason.
3. This class requires considerable effort and study time. Here are some **tips for improving your performance:**
 - ❖ **Laboratory instructors are an invaluable resource.** We are fortunate to have very experienced and knowledgeable laboratory instructors who are passionate about teaching the human body. Laboratory time will rarely be lecture-intensive, so please ask questions and allow them to guide you in learning the material. They are interested in your success.
 - ❖ **Students should prepare for lab by reading the objectives and material for the pertinent lab each week BEFORE you come to lab.** This is crucial. The prepared student will maximize laboratory time and experience.
 - ❖ **You should bring your lab manual or white sheet handouts and your textbook to lab each week.**
 - ❖ **Quizzes, midterm, and final practical exams may include ANY term listed in the white sheet handouts or lab manual.** It is your responsibility to identify every term on any specimen or model available. Instructors and laboratory aides are there to help you.
 - ❖ **Expect a practical quiz each week,** in which you will be tested with models, dissected specimens, and cadavers.

- ❖ **Spelling anatomical terms correctly is considered an integral part of the course.** Spelling errors include: improper use of singular/plural, confusing or omitting right/left, or artery/vein/nerve, illegible handwriting. Spelling policy will be explained in full on your syllabus. Practice spelling as well as identification.
 - ❖ Be an active learner, observe all models and specimens, and use your lab time to the fullest extent. **Students who leave early generally have not fully investigated the material.**
 - ❖ **Set aside time for studying each day** at home, during open lab, or in the libraries or STEM center. Cramming will not work well for this course.
 - ❖ **Consider forming a study group.**
4. Additional resources available to students:
- ❖ **Open labs for additional study time are provided on each campus, multiple times per week.** The open lab schedule is provided on the www.slccanatomy.com website. Space is limited in open labs and fire codes will be respected, so you may be turned away if open lab is at capacity.
 - ❖ **There are multiple models and skeletons available for study in the Dumke Center for STEM learning on Redwood campus, and in SLCC libraries on Redwood and Jordan campuses.**
 - ❖ **Student laboratory aides** will be available in most labs. These are successful Human Anatomy students from past semesters, who are enrolled in a lab aide training class (BIOL2327) or employed as paid aides, and they will guide you to the best of their abilities. Please utilize them, and be respectful of them. They are great resources, but they are still learning.
 - ❖ This website is provided for student use: www.slccanatomy.com. The site contains the following student resources:
 - **A calendar** of the activities to be covered each week, and a schedule of open lab times.
 - **PowerPoint presentations** are provided for each week's activities.
 - **White sheet terms lists for each week's activities and a link for purchasing a printed version of the Laboratory Manual.**
 - **Current contact information for all laboratory instructors, the laboratory coordinator, and the curriculum director.**
 - **Current lists of models available for study in the campus libraries.**
 - There is no substitute for hands-on time in laboratories studying cadavers, but in order to aid your cadaver study, we have provided an **online photographic prosection database of the cadavers in SLCC's Human Anatomy laboratories.** These images are password-protected. You must obtain the password from your lecture or laboratory instructor.

All images created by the SLCC Anatomy team or public domain from Wikimedia Commons.

ACTIVITY 1: INTRODUCTION AND ANATOMICAL TERMS

Objectives:

- 1) How to get ready: Read **Chapter 1, McKinley et al., Human Anatomy, 5e**. All text references are for this textbook.
- 2) Obtain and review laboratory syllabus, including instructor contact information, laboratory schedule, grading policies and safety procedures.
- 3) Review basic anatomical terminology, including regional terms, body cavities, directional terms, and body planes.
- 4) ★ *Fill in the description for each term in the tables.*
- 5) ★ Label regional terms on Figures 1 and 2.
- 6) Before next class: Preview histology lists from SLCC Anatomy Laboratory website or your printed laboratory manual and your textbook. You will be learning 26 different tissues; preparation is crucial.

TABLE 1. REGIONAL TERMS

TERM	DESCRIPTION & TEXT REFERENCES pp. 13-14, table 1.3; fig. 1.8
AXIAL	
<input type="checkbox"/> cephalic	
<input type="checkbox"/> frontal	
<input type="checkbox"/> occipital	
<input type="checkbox"/> parietal	
<input type="checkbox"/> temporal	
<input type="checkbox"/> auricular	
<input type="checkbox"/> facial	
<input type="checkbox"/> buccal	
<input type="checkbox"/> nasal	
<input type="checkbox"/> oral	
<input type="checkbox"/> mental	
<input type="checkbox"/> orbital	
<input type="checkbox"/> cervical	
<input type="checkbox"/> thoracic	
<input type="checkbox"/> pectoral	
<input type="checkbox"/> axillary	
<input type="checkbox"/> mammary	
<input type="checkbox"/> sternal	
<input type="checkbox"/> back/dorsal	
<input type="checkbox"/> scapular	
<input type="checkbox"/> vertebral	
<input type="checkbox"/> sacral	
<input type="checkbox"/> abdominal	
<input type="checkbox"/> pelvic	
<input type="checkbox"/> inguinal	
<input type="checkbox"/> pubic	

Table 1, continued: REGIONAL TERMS

TERM	DESCRIPTION & TEXT REFERENCES pp. 13-14, table 1.3; fig. 1.8
APPENDICULAR	
Superior Limb	
<input type="checkbox"/> deltoid	
<input type="checkbox"/> brachial	
<input type="checkbox"/> antecubital	
<input type="checkbox"/> olecranal	
<input type="checkbox"/> antebrachial	
<input type="checkbox"/> manus	
<input type="checkbox"/> carpal	
<input type="checkbox"/> dorsum of hand	
<input type="checkbox"/> palmar	
<input type="checkbox"/> digital	
<input type="checkbox"/> pollex	
Inferior Limb	
<input type="checkbox"/> gluteal	
<input type="checkbox"/> coxal	
<input type="checkbox"/> femoral	
<input type="checkbox"/> patellar	
<input type="checkbox"/> popliteal	
<input type="checkbox"/> crural	
<input type="checkbox"/> sural	
<input type="checkbox"/> pes	
<input type="checkbox"/> tarsal	
<input type="checkbox"/> calcaneal	
<input type="checkbox"/> dorsum of foot	
<input type="checkbox"/> plantar surface of foot	
<input type="checkbox"/> digital	
<input type="checkbox"/> hallux	

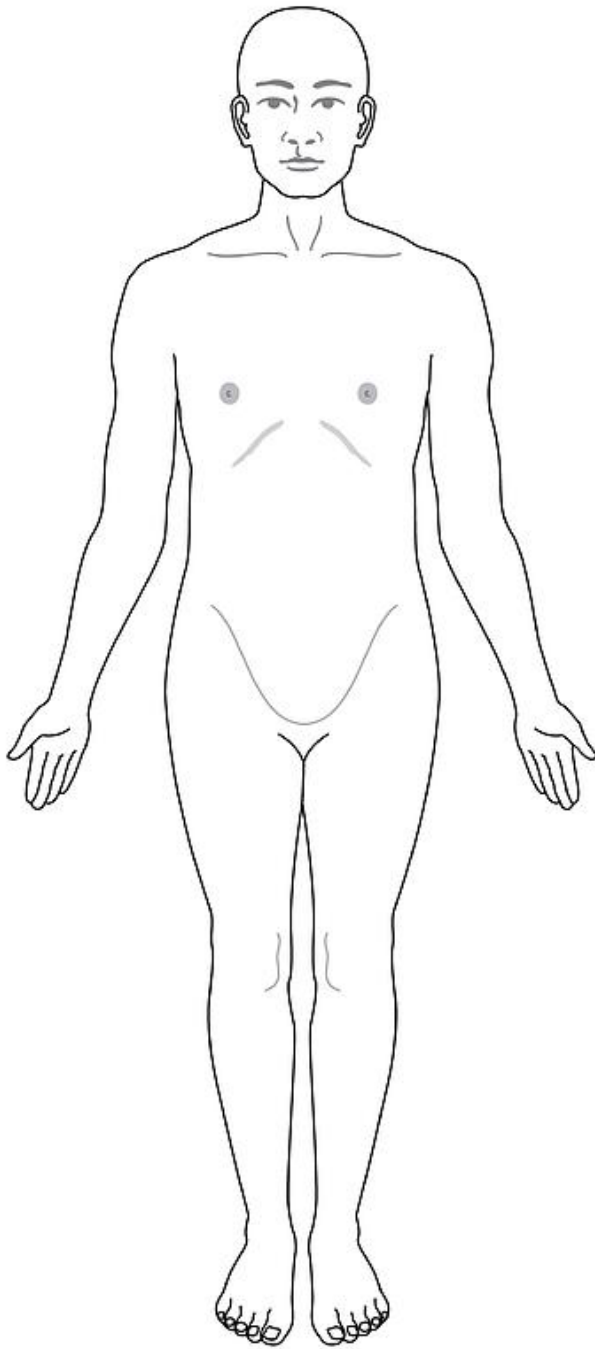


Figure 1: Human body, anterior view

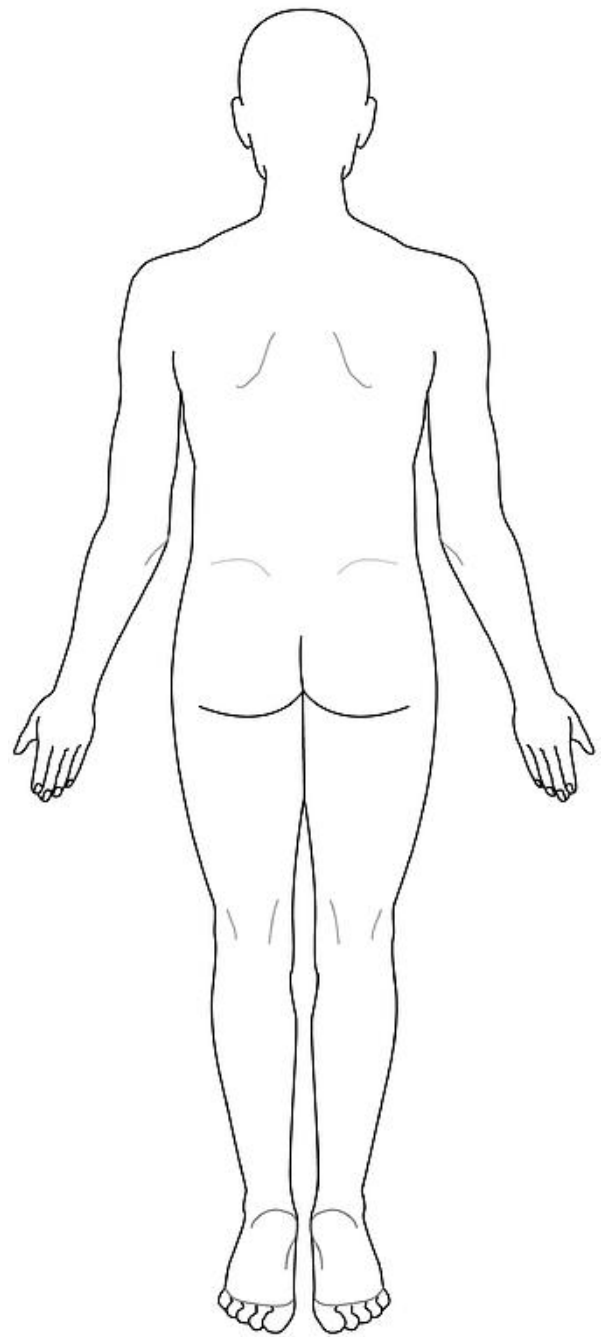


Figure 2: Human body, posterior view

★ Label REGIONAL TERMS from Table 1 on the diagrams above.

TABLE 2. BODY CAVITIES AND REGIONS

TERM	DESCRIPTIONS & TEXT REFERENCES pp. 15-17, fig. 1.9, 1.10, table 1.4
<input type="checkbox"/> dorsal cavity <i>or</i> posterior aspect	
<input type="checkbox"/> cranial cavity	
<input type="checkbox"/> vertebral canal/ cavity	
<input type="checkbox"/> ventral cavity	
<input type="checkbox"/> thoracic cavity	
<input type="checkbox"/> mediastinum	not a true cavity; a space between the left and right pleural cavities
<input type="checkbox"/> pericardial cavity	
<input type="checkbox"/> pleural cavities (left and right)	
<input type="checkbox"/> diaphragm	not a cavity; a skeletal muscle that divides the thoracic and abdominopelvic cavities
<input type="checkbox"/> abdominopelvic cavity	
<input type="checkbox"/> abdominal cavity	
<input type="checkbox"/> peritoneal cavity	
<input type="checkbox"/> pelvic cavity	

TABLE 3. ABDOMINOPELVIC REGIONS

TERM	DESCRIPTIONS & TEXT REFERENCES p. 17, fig. 1.11
epigastric	
hypochondriac (left and right)	
umbilical	
lumbar (left and right)	
hypogastric	
iliac (left and right)	

TABLE 4. DIRECTIONAL TERMS

TERM	DESCRIPTIONS & TEXT REFERENCE PP. 12-13, fig. 1.7, table 1.2
axial/ appendicular	
anterior/ posterior	
ventral/ dorsal	
superior/ inferior	
cephalic (cranial)/ caudal	
superficial/ deep	
external/ internal	
proximal/ distal	
medial/ lateral	
supine/ prone	
right/ left	

Table 5. Body Planes

TERM	DESCRIPTIONS & TEXT REFERENCE P. 11, fig. 1.5
<input type="checkbox"/> transverse/ horizontal	
<input type="checkbox"/> sagittal	
<input type="checkbox"/> midsagittal/ median	
<input type="checkbox"/> parasagittal	
<input type="checkbox"/> coronal/ frontal	
<input type="checkbox"/> oblique	