

ACTIVITY 11: RESPIRATORY AND DIGESTIVE SYSTEMS

OBJECTIVES:

- 1) **How to get ready:** Read [Chapters 25 and 26, McKinley et al., Human Anatomy, 5e](#). All text references are for this textbook.
- 2) Identify structures listed in the gross anatomy of the respiratory system on models and cadavers.
- 3) Histology: Examine and sketch a slide or photo of lung tissue and identify indicated structures.
- 4) Identify structures listed in the gross anatomy of the digestive system on models and cadavers. **YOU MUST BRING GLOVES FOR THIS ACTIVITY.**
- 5) ★ **At home assignment:** Identify histology slides and structures from various digestive system histology slides or photos.
- 6) **Before next class:** Preview Urinary and Reproductive terms lists from SLCC Anatomy Laboratory website or your printed laboratory manual and your textbook.

RESPIRATORY SYSTEM

TABLE 1. UPPER RESPIRATORY TRACT: Includes the nose, nasal cavity, paranasal sinuses, and pharynx and associated structures.

STRUCTURE	TEXTBOOK REFERENCE AND NOTES
NASAL CAVITY	described: p. 744 fig. 25.2
<input type="checkbox"/> nostril	
<input type="checkbox"/> vestibule	
<input type="checkbox"/> superior nasal concha (pl. <i>conchae</i>) and superior meatus	
<input type="checkbox"/> middle nasal concha and middle meatus	
<input type="checkbox"/> inferior nasal concha and inferior meatus	
PARANASAL SINUSES	described: p. 744 fig. 7.3, 25.2, 25.3
<input type="checkbox"/> sphenoidal sinus	
<input type="checkbox"/> ethmoidal sinuses	
<input type="checkbox"/> frontal sinus	
<input type="checkbox"/> maxillary sinuses	
PHARYNX (common space used by respiratory and digestive systems)	described: pp. 744,746 fig. 25.1, 25.2
<input type="checkbox"/> nasopharynx	
<input type="checkbox"/> opening of auditory tube	described: p. 746 fig. 25.2
<input type="checkbox"/> hard palate	described: p. 776 fig. 26.3
<input type="checkbox"/> soft palate (divides nasopharynx and oropharynx)	
<input type="checkbox"/> oropharynx	described: p. 746 fig. 25.2
<input type="checkbox"/> hyoid bone (divides oropharynx and laryngopharynx)	described: p. 201 fig. 7.26
<input type="checkbox"/> laryngopharynx	described: p. 746; fig. 25.2

TABLE 2. LOWER RESPIRATORY TRACT: Conducting airways – larynx through bronchioles. [Table 25.2](#)

STRUCTURE	TEXTBOOK REFERENCE AND NOTES
<input type="checkbox"/> LARYNX	
<input type="checkbox"/> epiglottis	described: p. 748 fig. 25.2, 25.4
<input type="checkbox"/> rima glottidis	described: p. 748 fig. 25.5
<input type="checkbox"/> glottis	
<input type="checkbox"/> thyroid cartilage and laryngeal prominence	described: p. 748 fig. 25.2, 25.4, 25.5
<input type="checkbox"/> corniculate cartilage	
<input type="checkbox"/> cricoid cartilage	
<input type="checkbox"/> arytenoid cartilages (covered by muscles)	
<input type="checkbox"/> vestibular ligaments/folds (false vocal cords)	
<input type="checkbox"/> vocal ligaments/folds (true vocal cords)	
<input type="checkbox"/> TRACHEA	
<input type="checkbox"/> tracheal cartilages	
BRONCHIAL TREE	described: pp. 752-753 fig. 25.7
<input type="checkbox"/> main (<u>or</u> primary) bronchus (pl. bronchi)	
<input type="checkbox"/> lobar (<u>or</u> secondary) bronchus (2 to left, 3 to right lung)	
<input type="checkbox"/> segmental (<u>or</u> tertiary) bronchus (lead to respiratory bronchioles and alveoli)	

TABLE 3. ALVEOLI AND THE RESPIRATORY MEMBRANE: Obtain a histology slide or photo of bronchioles and alveoli and identify the following structures.

STRUCTURE	TEXTBOOK REFERENCE AND SKETCH
<input type="checkbox"/> respiratory bronchioles	described: p. 754 fig. 25.8b, 25.9
<input type="checkbox"/> alveolar ducts	
<input type="checkbox"/> alveolar sacs	
<input type="checkbox"/> alveoli (sing. <i>alveolus</i>)	
<input type="checkbox"/> pulmonary capillaries	

TABLE 4. LUNGS AND ASSOCIATED STRUCTURES

STRUCTURE	TEXTBOOK REFERENCE AND NOTES	
<input type="checkbox"/> visceral pleura	described: p. 756 fig. 25.10	
<input type="checkbox"/> pleural cavity		
<input type="checkbox"/> parietal pleura		
LUNGS	described: pp. 756-757 fig. 25.11	
<input type="checkbox"/> right lung (3 lobes)		
<input type="checkbox"/> superior lobe		
<input type="checkbox"/> horizontal fissure		
<input type="checkbox"/> middle lobe		
<input type="checkbox"/> oblique fissure		
<input type="checkbox"/> inferior lobe		
<input type="checkbox"/> hilum		
<input type="checkbox"/> pulmonary arteries and veins		
<input type="checkbox"/> main (<i>or</i> primary) bronchus (pl. <i>bronchi</i>)		
<input type="checkbox"/> left lung (2 lobes)		
<input type="checkbox"/> superior lobe		
<input type="checkbox"/> cardiac notch		
<input type="checkbox"/> oblique fissure		
<input type="checkbox"/> inferior lobe		
<input type="checkbox"/> hilum		
<input type="checkbox"/> pulmonary arteries and veins		
<input type="checkbox"/> main (<i>or</i> primary) bronchus (pl. <i>bronchi</i>)		
<input type="checkbox"/> diaphragm		described: pp. 341,761 fig. 11.13, 25.10, 25.1

DIGESTIVE SYSTEM

TABLE 5. ORAL CAVITY, SALIVARY GLANDS, AND ASSOCIATED STRUCTURES

STRUCTURE	TEXTBOOK REFERENCE AND NOTES
ORAL CAVITY	described: pp. 775-776 fig. 26.3, Table 26.3
<input type="checkbox"/> upper and lower lips	
<input type="checkbox"/> superior labial frenulum	
<input type="checkbox"/> inferior labial frenulum	
<input type="checkbox"/> vestibule	
<input type="checkbox"/> teeth	
<input type="checkbox"/> gingivae	
<input type="checkbox"/> hard and soft palates	
<input type="checkbox"/> uvula	
<input type="checkbox"/> tongue	
<input type="checkbox"/> lingual frenulum	
<input type="checkbox"/> palatine tonsils	
<input type="checkbox"/> lingual tonsils	
<input type="checkbox"/> pharyngeal tonsils	
SALIVARY GLANDS	described: pp. 776, 778 fig. 26.1, 26.4
<input type="checkbox"/> parotid salivary glands	
<input type="checkbox"/> parotid duct and orifice	
<input type="checkbox"/> sublingual salivary glands	
<input type="checkbox"/> sublingual ducts and orifices	
<input type="checkbox"/> submandibular salivary glands	
<input type="checkbox"/> submandibular duct and orifice	

TABLE 6. ESOPHAGUS THROUGH STOMACH

STRUCTURE	TEXTBOOK REFERENCE AND NOTES
<input type="checkbox"/> esophagus	described: pp. 785-786 fig. 26.10
<input type="checkbox"/> inferior esophageal (<u>or</u> cardiac) sphincter	
<input type="checkbox"/> stomach	described: p. 787 fig. 26.12
<input type="checkbox"/> cardia	
<input type="checkbox"/> fundus	
<input type="checkbox"/> greater curvature	
<input type="checkbox"/> lesser curvature	
<input type="checkbox"/> pylorus	
<input type="checkbox"/> pyloric sphincter	
<input type="checkbox"/> gastric folds (<u>or</u> rugae)	
<input type="checkbox"/> greater omentum	described: p. 781 fig. 26.7, 26.8
<input type="checkbox"/> lesser omentum	

TABLE 7. SMALL INTESTINE, LARGE INTESTINE, RECTUM AND ANUS

STRUCTURE	TEXTBOOK REFERENCE AND NOTES
<input type="checkbox"/> SMALL INTESTINE	described: p. 791
<input type="checkbox"/> duodenum	fig. 26.7, 26.14, 26.15, 26.20
<input type="checkbox"/> hepatopancreatic ampulla	
<input type="checkbox"/> major duodenal papilla (opening to main pancreatic duct)	
<input type="checkbox"/> circular folds (<i>or</i> plicae circulares)	
<input type="checkbox"/> jejunum	
<input type="checkbox"/> circular folds	
<input type="checkbox"/> ileum	
<input type="checkbox"/> circular folds (plicae circulares)	
<input type="checkbox"/> mesentery proper (<i>or</i> intestinal mesentery)	described: p. 781 fig. 26.7, 26.8
<input type="checkbox"/> LARGE INTESTINE (includes cecum and colon)	described: pp. 793-794
<input type="checkbox"/> cecum (inferior to ileocecal valve)	fig. 26.16
<input type="checkbox"/> vermiform appendix	
<input type="checkbox"/> ileocecal valve (<i>or</i> sphincter)	
<input type="checkbox"/> colon (superior to ileocecal valve)	
<input type="checkbox"/> ascending colon and right colic flexure	
<input type="checkbox"/> transverse colon and left colic flexure	
<input type="checkbox"/> descending colon and sigmoid flexure	
<input type="checkbox"/> sigmoid colon	
<input type="checkbox"/> teniae coli	described: p. 796
<input type="checkbox"/> haustrum (pl. <i>haustra</i>)	fig. 26.16
<input type="checkbox"/> RECTUM AND ANUS	described: pp. 794-795 fig. 26.16b

TABLE 8. ACCESSORY DIGESTIVE STRUCTURES AND BILIARY SYSTEM

STRUCTURE	TEXTBOOK REFERENCE
<input type="checkbox"/> liver	described: pp. 797-798 fig. 26.18
<input type="checkbox"/> right and left lobes	
<input type="checkbox"/> falciform ligament (separates right and left lobes)	
<input type="checkbox"/> round ligament of the liver (<i>or</i> ligamentum teres)	
<input type="checkbox"/> porta hepatis	
<input type="checkbox"/> common hepatic duct	
<input type="checkbox"/> hepatic portal vein	
<input type="checkbox"/> hepatic artery proper	described: pp. 798-803 fig. 26.18, 26.20, 26.21
<input type="checkbox"/> gallbladder	
<input type="checkbox"/> cystic duct	
<input type="checkbox"/> common bile duct	
<input type="checkbox"/> pancreas	
<input type="checkbox"/> main pancreatic duct	
<input type="checkbox"/> accessory pancreatic duct	

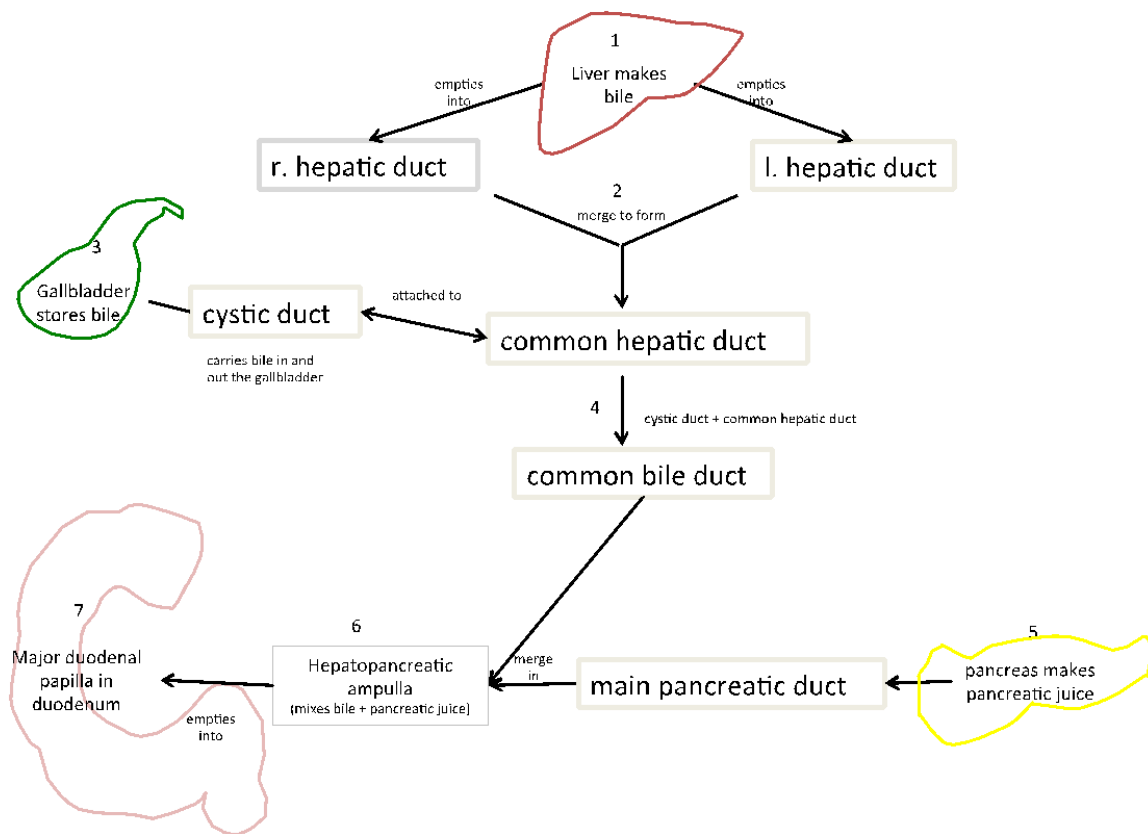


Figure 1. Biliary System Flowchart

★ HISTOLOGY OF THE DIGESTIVE SYSTEM AT HOME ASSIGNMENT

- Be able to distinguish histology slides from each of the following digestive organs: esophagus, stomach, duodenum, jejunum, ileum, colon, pancreas, liver.
- Identify the indicated structures on histology slides of different organs of the digestive system. In addition to your textbook photos, use the link provided under Activity 11 on the slccanatomy.com webpage to access a PowerPoint presentation with all of the following digestive system histology slides.

TABLE 9. HISTOLOGY OF THE GI TRACT: Identify the following structures and layers on a histology slide or photo and a model of a cross section of the GI tract, and be able to differentiate slides taken from the following organs.

STRUCTURE	TEXTBOOK REFERENCE AND SKETCHES
IDENTIFY THE FOLLOWING STRUCTURES ON <u>ALL</u> GI TRACT CROSS SECTION SLIDES AND ON IN-CLASS MODEL	
<input type="checkbox"/> lumen	pp. 782-783 fig. 26.9
<input type="checkbox"/> mucosa	
<input type="checkbox"/> submucosa	
<input type="checkbox"/> muscularis	
<input type="checkbox"/> adventitia/ serosa	
ESOPHAGUS HISTOLOGY: distinguishing features	
<input type="checkbox"/> mucosa is composed of nonkeratinized stratified squamous epithelium	fig. 26.10b
<input type="checkbox"/> adventitia	
STOMACH HISTOLOGY: distinguishing features	
<input type="checkbox"/> mucosa is composed of simple columnar epithelium with	fig. 26.13a & b
<input type="checkbox"/> gastric pits	
<input type="checkbox"/> gastric glands	
<input type="checkbox"/> muscularis with oblique, circular, and longitudinal layers	
SMALL INTESTINE HISTOLOGY: distinguishing features	
<input type="checkbox"/> mucosa of simple columnar epithelium with	fig. 26.15
<input type="checkbox"/> intestinal villi (with microvilli)	
<input type="checkbox"/> intestinal glands	
<input type="checkbox"/> goblet cells (more numerous toward distal end of GI tract)	
<input type="checkbox"/> Peyer patches (primarily in ileum)	
<input type="checkbox"/> lacteal	
LARGE INTESTINE HISTOLOGY: distinguishing features	
<input type="checkbox"/> mucosa of simple columnar epithelium without intestinal villi	fig. 26.17
<input type="checkbox"/> abundant goblet cells	
<input type="checkbox"/> abundant intestinal glands	

TABLE 10. HISTOLOGY OF ACCESSORY DIGESTIVE STRUCTURES

STRUCTURE	TEXTBOOK REFERENCE AND SKETCHES
LIVER HISTOLOGY: distinguishing features	fig. 26.19a-c
<input type="checkbox"/> portal triad	
<input type="checkbox"/> branch of hepatic portal vein	
<input type="checkbox"/> branch of hepatic artery	
<input type="checkbox"/> branch of bile duct	
<input type="checkbox"/> hepatic lobule	
<input type="checkbox"/> hepatocytes	
<input type="checkbox"/> sinusoid capillaries	
<input type="checkbox"/> central vein leading to hepatic veins	
PANCREAS HISTOLOGY: distinguishing features	fig. 26.20
<input type="checkbox"/> pancreatic acinus (exocrine function)	
<input type="checkbox"/> pancreatic islet (<u>or</u> islet of Langerhans) (endocrine function)	
<input type="checkbox"/> portal triad	