

ACTIVITY 9: BLOOD AND HEART

OBJECTIVES:

- 1) How to get ready: Read **Chapters 21 & 22, McKinley et al., Human Anatomy, 5e**. All text references are for this textbook. Read dissection instructions BEFORE YOU COME TO LAB.
- 2) **Histology:** Identify elements in a prepared slide or photo of stained human blood.
- 3) **Observe and identify the human heart and other major structures in the thoracic cavity of a human cadaver.**
- 4) **Identify structures on models of a human heart.**
- 5) **★ Perform a dissection on a preserved sheep heart or fresh pig heart. YOU MUST BRING GLOVES FOR THIS ACTIVITY.**
- 6) Before next class: **Preview Vessels terms lists from SLCC Anatomy Laboratory website or your printed laboratory manual and your textbook. You will be learning many vessels, so preparation is important.**

BLOOD

TABLE 1. BLOOD HISTOLOGY

| STRUCTURE                                      | TEXTBOOK REFERENCE AND SKETCH  |
|--|--|
| <input type="checkbox"/> leukocytes            | <b>described: pp. 642-644; 645-647<br/>fig. 21.2, Table 21.2, 21.3</b> |
| <input type="checkbox"/> neutrophil            |  |
| <input type="checkbox"/> eosinophil            |  |
| <input type="checkbox"/> basophil              |  |
| <input type="checkbox"/> lymphocyte            |  |
| <input type="checkbox"/> monocyte              |  |
| <input type="checkbox"/> erythrocyte           |  |
| <input type="checkbox"/> platelet /thrombocyte |  |

## HEART

**TABLE 2.** HEART POSITION WITHIN THE THORACIC CAVITY: **Observe a model of a human thorax and/or the thoracic cavity of a human cadaver and identify the following structures in and around the pericardial cavity.**

| STRUCTURE   | TEXTBOOK REFERENCE                  |
|---|-------------------------------------|
| <input type="checkbox"/> diaphragm                                      | described: pp. 652-653<br>fig. 22.2 |
| <input type="checkbox"/> heart within pericardium                       |                                     |
| <input type="checkbox"/> lungs within pleural cavities (left and right) |                                     |
| <input type="checkbox"/> mediastinum                                    |                                     |
| <input type="checkbox"/> trachea  |                                     |
| <input type="checkbox"/> esophagus                                      |                                     |

**TABLE 3.** THE PERICARDIUM AND HEART WALL LAYERS

| STRUCTURE  | TEXTBOOK REFERENCE & NOTES          |
|--|-------------------------------------|
| <input type="checkbox"/> pericardium                               | described: pp. 652-654<br>fig. 22.3 |
| <input type="checkbox"/> fibrous pericardium                       |                                     |
| <input type="checkbox"/> serous pericardium                        |                                     |
| <input type="checkbox"/> parietal layer                            |                                     |
| <input type="checkbox"/> pericardial cavity                        |                                     |
| <input type="checkbox"/> visceral layer ( <u>or</u><br>epicardium) |                                     |
| <input type="checkbox"/> myocardium                                |                                     |
| <input type="checkbox"/> endocardium                               |                                     |

TABLE 4. HEART STRUCTURES

| STRUCTURE  | TEXTBOOK REFERENCE & NOTES                      |
|--|---|
| <b>RIGHT HEART: contains blood returning from the body and heart muscle, and destined for the pulmonary capillary beds</b> |   |
| <input type="checkbox"/> superior vena cava (receives blood from head and arms)  | described: pp. 658-659<br>fig. 22.5, 22.6, 22.7 |
| <input type="checkbox"/> inferior vena cava (receives blood from trunk and legs)   |   |
| <input type="checkbox"/> coronary sinus (blood from heart muscle)  |   |
| <input type="checkbox"/> right atrium (and right auricle)  |   |
| <input type="checkbox"/> right atrioventricular (AV) valve (tricuspid)   |   |
| <input type="checkbox"/> right ventricle   |   |
| <input type="checkbox"/> pulmonary semilunar valve   |   |
| <input type="checkbox"/> pulmonary trunk   |   |
| <input type="checkbox"/> pulmonary arteries (right and left)   |   |
| <b>LEFT HEART: contains blood returning from the lungs and destined for the systemic capillary beds</b>                    |   |
| <input type="checkbox"/> pulmonary veins (right and left)  | described: pp. 659-660<br>fig. 22.5, 22.6, 22.7 |
| <input type="checkbox"/> left atrium (and left auricle)  |   |
| <input type="checkbox"/> left atrioventricular valve (bicuspid or mitral)  |   |
| <input type="checkbox"/> left ventricle  |   |
| <input type="checkbox"/> aortic semilunar valve  |   |
| <input type="checkbox"/> aorta   |   |
| <b>OTHER HEART STRUCTURES</b>  |   |
| EXTERNAL STRUCTURES  | described: pp. 652,654<br>fig. 22.5             |
| <input type="checkbox"/> apex of heart   |   |
| <input type="checkbox"/> base of heart   |   |
| <input type="checkbox"/> coronary sulcus   |   |
| <input type="checkbox"/> interventricular sulcus (anterior and posterior)  |   |
| INTERNAL STRUCTURES  |   |
| <input type="checkbox"/> interatrial septum  |   |
| <input type="checkbox"/> fossa ovalis  |   |
| <input type="checkbox"/> interventricular septum   |   |
| <input type="checkbox"/> chordae tendineae   |   |
| <input type="checkbox"/> papillary muscles   |   |
| <input type="checkbox"/> trabeculae carneae  |   |

**TABLE 5. CORONARY CIRCULATION: The heart wall receives blood from the ascending aorta, and returns blood to the right atrium, and is thus considered part of systemic circulation.**

| STRUCTURE   | TEXTBOOK REFERENCE & NOTES           |
|---|--------------------------------------|
| ARTERIAL SUPPLY TO THE HEART WALL<br>(branches of the ascending aorta)                                    | described: p. 660<br>fig 22.5, 22.9a |
| <input type="checkbox"/> right coronary artery  |                                      |
| <input type="checkbox"/> marginal artery  |                                      |
| <input type="checkbox"/> posterior interventricular artery  |                                      |
| <input type="checkbox"/> left coronary artery   |                                      |
| <input type="checkbox"/> circumflex artery  |                                      |
| <input type="checkbox"/> anterior interventricular artery<br>( <u>or</u> left anterior descending artery) | fig 22.5, 22.9b                      |
| VENOUS RETURN FROM THE HEART WALL (to the right atrium)   |                                      |
| <input type="checkbox"/> great cardiac vein   |                                      |
| <input type="checkbox"/> middle cardiac vein  |                                      |
| <input type="checkbox"/> small cardiac vein   |                                      |
| <input type="checkbox"/> coronary sinus   |                                      |



Helpful Terminology for Heart

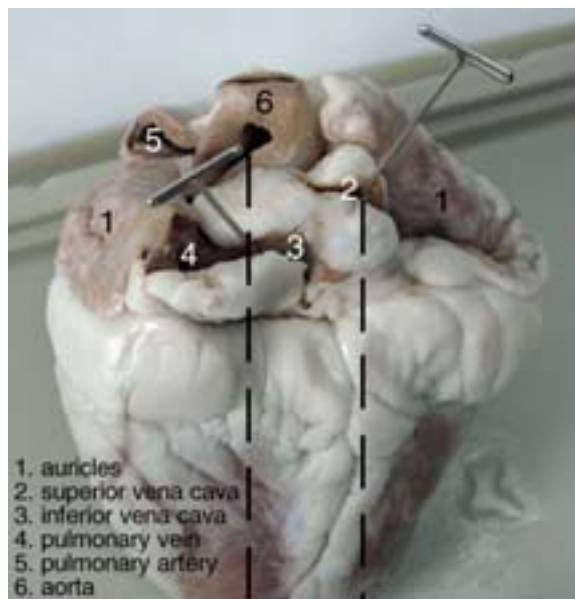
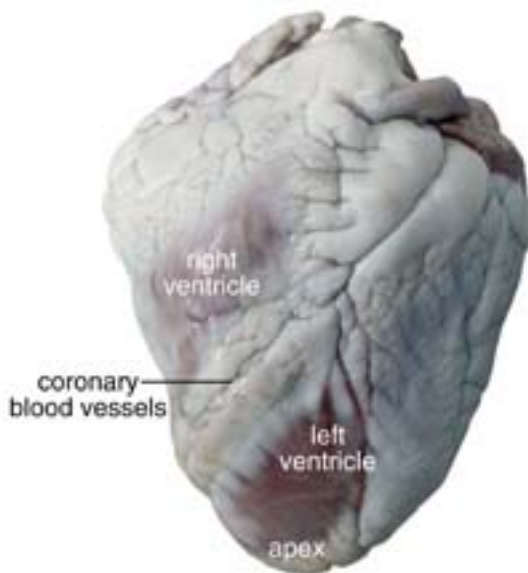
| Anatomical Terms     | Description                            |
|----------------------|--|
| atrium               | entrance hall                          |
| chorda/chordae       | cord                                   |
| circumflex           | bend, bent around                      |
| carneae              | fleshy                                 |
| marginal             | margin = border or edge of a surface   |
| papillary            | nipple-like                            |
| septum               | wall, partition                        |
| trabecula/trabeculae | beam; supporting fibers on a structure |
| ventricle            | small belly                            |

★ CARDIOVASCULAR SYSTEM: SHEEP HEART OR PIG HEART OBSERVATION AND DISSECTION

OBSERVATION: External anatomy of the heart

1. Identify the right and left sides of the heart. Look closely and on one side you will see a diagonal line of blood vessels that divide the heart. The half that includes all of the apex (pointed end) of the heart is the left side. Confirm this by squeezing each half of the heart. The left half will feel much firmer and more muscular than the right side. The left side of the heart is stronger because it has to pump blood to the whole body. The right side only pumps blood to the lungs.

2. Turn the heart so that the right side is on your right, as if it were in your body. Examine the flaps of darker tissue on the top of the heart. These ear-like flaps are called auricles. Find the large opening at the top of the heart next to the right auricle. This is the opening to the superior vena cava, which brings blood from the top half of the body to the right atrium. Stick a probe down this vessel. You should feel it open into the right atrium.



Down and to the left of the superior vena cava there is another blood vessel opening. Insert your probe into this; it should also lead into the right atrium. This is the inferior vena cava, which brings blood from the lower tissues. You can also see another blood vessel next to the left auricle. This is a pulmonary vein that brings blood from the lungs into the left atrium.

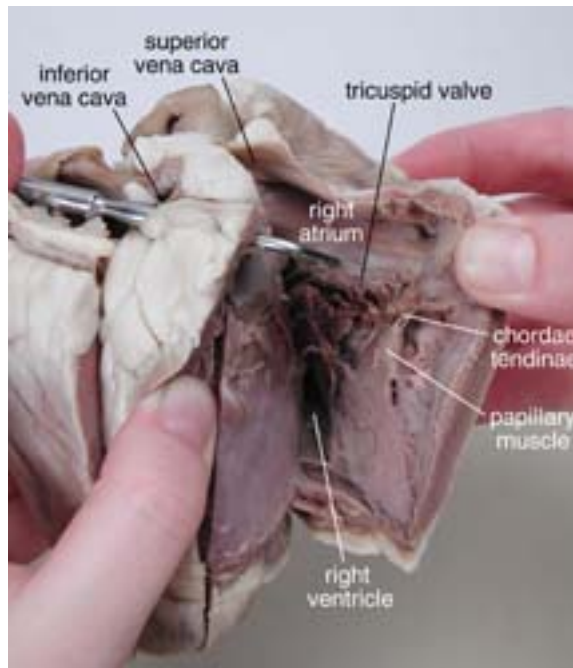
3. Sticking straight up from the center of the heart is the largest blood vessel you will see. This is the aorta, which takes oxygenated blood from the left ventricle to the rest of the body (the ventricles are the lower chambers of the heart).

4. Behind and to the left of the aorta there is another large vessel. This is the pulmonary trunk (artery), which takes blood from the right ventricle to the lungs.

DISSECTION: Internal anatomy of the sheep heart. After identifying the external anatomical structures in a sheep heart, perform a dissection of the sheep heart as described.

1. Insert your dissecting scissors or scalpel into the superior vena cava and make an incision down through the wall of the right atrium and ventricle, as shown by the dotted line in the external heart picture. Pull the two sides apart and look for three flaps of membrane. These membranes form the tricuspid valve between the right atrium and the right ventricle. The membranes are connected to flaps of muscle called the papillary muscles by tendons called the chordae tendineae or "heartstrings." This valve allows blood to enter the ventricle from the atrium, but prevents backflow from the ventricle into the atrium.

2. Insert your probe into the pulmonary trunk and see it come through to the right ventricle. Make an incision down through this artery and look inside it for three small membranous pockets. These form the pulmonary semilunar valve, which prevents blood from flowing back into the right ventricle.



3. Insert your dissecting scissors or scalpel into the left auricle at the base of the aorta and make an incision down through the wall of the left atrium and ventricle, as shown by the dotted line in the external heart picture. Locate the mitral valve (bicuspid valve) between the left atrium and ventricle. This will have two flaps of membrane connected to papillary muscles by tendons.

4. Insert a probe into the aorta and observe where it connects to the left ventricle. Make an incision up through the aorta and examine the inside carefully for three small membranous pockets. These form the aortic semilunar valve, which prevents blood from flowing back into the left ventricle.

***FOLLOWING DISSECTION, DISPOSE OF SCALPEL BLADES IN APPROPRIATE SHARPS CONTAINER AND WASH ALL DISSECTION INSTRUMENTS WITH SOAP AND WATER, THEN DRY THOROUGHLY AND PUT INSTRUMENTS AWAY. DISPOSE OF SHEEP HEARTS ACCORDING TO YOUR INSTRUCTOR'S DIRECTIONS.***